

A Case Report of Death Claimed Due To Oral Polio Vaccine (OPV)

Raghvendra singh¹,
Raja Rupani¹,
Anoop Kumar Verma¹,
Mousami Singh¹,
Shiuli Rathore¹,
Heena Singh² and
Sangeeta Kumari¹

Abstract

To eradicate polio, India introduced special drive of OPV immunisation. We are describing a case of death claimed due to OPV, brought to mortuary at King George's Medical University, Lucknow, North India. Some religious communities oppose OPV drive continuously because, to them OPV seems to be an objectionable material and can lead to ill effects to their children. Hence, such type of cases need a careful examination as they can create panic in the society and media and jeopardise all attempts to eliminate polio. In this case, besides considering OPV, we also came across many factors like, subgaleal haemorrhage and bottle feeding. These factors could also be a cause of infant death, but after careful Post mortem examination, we found that the main culprit was feeding bottle.

Keywords: Oral Polio Vaccine; Newborn; Subgaleal haemorrhage; Bottle feeding.

Introduction

India has been declared polio free by WHO [1]. Polio Eradication efforts will continue till polio is globally eradicated. Some religious communities keep on objecting over polio vaccination drive. They think that polio vaccination may cause harm to their children. So it is very important to make them clear that nothing is harmful in polio drops and it is the responsibility of the leaders, of these religious communities, to remove misconceptions about use of vaccines to protect children of their community from this crippling disease. We describe a case of death claimed to be due to OPV, brought to mortuary at King George's Medical University, Lucknow, North India for expert autopsy. These cases can further consolidate the rumour that OPV contains objectionable material, which can lead to death of their children, otherwise all attempts to completely eliminate the polio from the world will go in vain.

Case Report

A case of death was reported due to OPV in a full term newborn male child, of one day old, weighing 1.8 kg, who was delivered by normal vaginal delivery at a hospital. At home, mother found her one day old infant dead in his crib, in supine position. One hour prior to incident, infant had received OPV. Hence she thought that the incidence occurred due to adverse effect of OPV. Death scene investigation and parental assessment did not yield any other specific cause of death. Autopsy was conducted & we came across the following findings -

- 1 Department of Forensic Medicine & Toxicology, KING GEORGE'S MEDICAL UNIVERSITY, Lucknow, U.P, India
- 2 Department Of Anatomy, KING GEORGE'S MEDICAL UNIVERSITY, LUCKNOW, U.P, INDIA

Corresponding author: Raghvendra singh

Department of Forensic Medicine & Toxicology, KING GEORGE'S MEDICAL UNIVERSITY, Lucknow, U.P, India.

✉ dr.raghvendrasingh@hotmail.com

Tel: 9532906700

Citation: Singh R, Rupani R, Verma AK. et al. A Case Report of Death Claimed Due To Oral Polio Vaccine (OPV). J Med toxicol clin forensic med. 2015, 1:1.

External findings

On examination there was no external finding, except bluish discolouration of nails

Internal findings

Visceras were congested. There was subgaleal collection of clotted blood at occipital area over the skull (area 5cm*4cm & volume 15-20 ml) [fig.-1]. Stomach was filled with semi digested curdy milk.

On opening trachea and bronchi we found a white coloured fluid (approx. 4-5 ml) at tracheo-bronchial region [Fig.-2]. This fluid was collected and sent for biochemical examination.

Cause of death was still not clear and hanged on three points -

First was any adverse reaction due to OPV

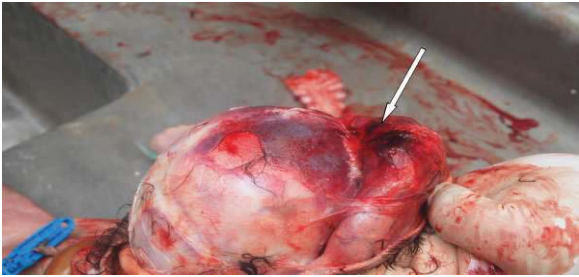


Figure 1 Subgaleal clotted blood.

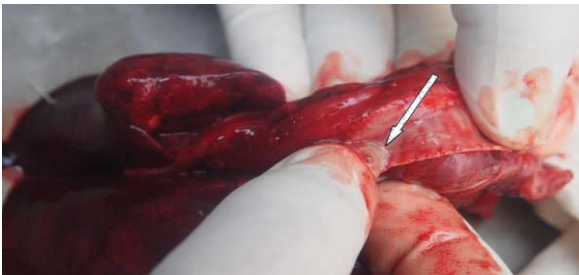

Figure 2 Fluid (milk) present in trachea.



Figure 3 Vial of suspected Polio vaccine.

Second was the blood loss due to subgaleal haemorrhage, as a consequence of instrumentation during vaginal delivery,

And thirdly, the fluid present at tracheo-bronchial region, similar to be milk which could be mucous also.

According to WHO, OPV is a heat sensitive vaccine. WHO uses a vaccine vial monitor to assess cold chain and prevent any expired vaccine to be introduced in immunisation. On examination of Vaccine vial monitor of suspected polio vaccine, inner Square was found to be lighter than outer circle proving maintenance of cold chain and also expiry date was not yet passed [Fig-3] [2]. Subgaleal haemorrhage is most serious complication of instrumental delivery, although rare, is associated with significant morbidity and mortality [3]. As it is not limited by suture line, the newborn can therefore lose up to 80% of their blood volume within the subaponeurotic space resulting in hypovolemic shock, acute anaemia, coagulopathy and death [4] but volume of subgaleal bleed was much less in this case. Thirdly we focussed on biochemical examination of fluid found at the tracheo-bronchial region. Initially, biuret test was done for screening of casein & result was found to be positive. To confirm this, we tested presence of casein in given fluid using ELISA SYSTEMS Casein Residue assay.

This assay confirmed the presence of milk in tracheo-bronchial region. Since gastro-oesophageal reflux is more common among new borns [5], so our next step was to detect the origin of this milk, that whether this milk reached at tracheo-bronchial junction as a result of gastro-oesophageal reflux or directly during faulty feeding. To differentiate it, we collected two samples - sample no.1 from stomach milk and sample no.2 from tracheo-bronchial milk and Ph test was performed on those samples. Result was surprising as Ph of both samples were different. Ph of sample no.1 was 4.02 while Ph of sample no.2 was 7.23. Difference in Ph & consistency indicated that the milk aspiration was caused directly by faulty feeding and not because of gastro-oesophageal reflux, as it was assumed earlier.

Discussion

According to WHO, OPV is contraindicated in families where children or their close contacts are immune compromised. The only grave complication of OPV is Vaccine Associated Paralytic Poliomyelitis [6]. Death may occur as a result of respiratory failure (5 to 10%) in vaccine derived polio virus but never as early as within 1-2 hour. Subgaleal haemorrhage although rare, is associated with significant morbidity and mortality. Uchil et al. in 2003 reported incidence of subgaleal haemorrhage in 0.4/1000 cases of spontaneous vaginal births and 5.9/1000 cases of vacuum births [4]. On careful examination of medical records at the time of delivery, we found that proper surveillance methods were adapted from the RANZCOG Recommendations [7] & there was no reported abnormality regarding - heart rate, respiratory rate, colour (pallor) and activity. So subgaleal haemorrhage can easily be excluded to be the cause of death. On proper history of feeding practices, we came to know that caregiver of infant, along with breast feeding also used feeding bottle, which has its own adverse effects. Improper breast feeding may cause infant death in some cases, especially in newborns with Low Birth Weight, if suck reflex is poorly developed [8]. But death by aspiration of milk in a term newborn with proper breast feeding is a rare event. It has been described earlier, that improper position during feeding of milk with bottle may lead to infant death if not supervised by caretaker [9]. On examining the bottle, we found one more significant point that, the rate of dispense of milk through that feeding bottle was unlikely very high. The very high rates of delivery of milk through this bottle definitely lead to pooling of milk into naso-oral cavity and from there it got aspirated into lungs and lead to death of this newborn.

Conclusion

Post mortem examination of these cases should be done carefully, on failing of which such type of cases can consolidate the rumours that OPV contains objectionable material, against some community, and all effect to counter polio will go into vain. Health workers should be specially trained to curb these type of rumours. Particularly, in this case scenario, they should inform people to be aware from such rumours and discourage use of feeding bottles and thus prevent newborn morbidity and mortality in developing country.

Declaration of funding information and conflict of interest, if any

There is no specific grant from any funding agency in the public,

commercial or profit and non profits sector. The author declares that there is no conflict of interest.

References

- 1 http://www.unicef.org/india/health_3729.htm. Accessed on 16.08.2015.
- 2 Samant Y, Lanjewar H, Parker D, Block L, Tomar GS, et al. (2007) Evaluation of the Cold-Chain for Oral Polio Vaccine in a Rural District of India. *Public Health Rep* 122:112-121.
- 3 Reid J (2007) Neonatal subgaleal hemorrhage. *Neonatal Netw* 26: 219-27.
- 4 Uchil D, Arulkumaran S (2003) Neonatal subgaleal hemorrhage and its relationship to delivery by vacuum extraction. *Obstet Gynecol Surv* 58: 687-93.
- 5 Fleming PJ, Blair PS, Pease A (2015) Sudden unexpected death in infancy: aetiology, pathophysiology, epidemiology and prevention in 2015. *Arch Dis Child* 100: 984-988.
- 6 http://www.who.int/vaccine_safety/initiative/tools/polio_vaccine_rates_information_sheet.pdf. Accessed on 17.08.2015
- 7 Royal Australian and New Zealand College of Obstetricians and Gynaecologists. Prevention Detection and Treatment of Subgaleal Haemorrhage in the Newborn. 2009; C-Obs 28.
- 8 Hendrik HD (2013) *Sucking-pads and primitive sucking reflex*. *Neonatal Perinatal Med* 6: 281-283.
- 9 Kibayashi K, Iwadata K, Shojo H (2004) Milk aspiration in an infant during supine bottle feeding: a case report *Med Sci Law*. 44: 272-5.